

The Effect of Aloe Vera Oral Administration on Cutaneous Wound Healing in Type 2 Diabetic Rats

Ayman ATIBA^{1,2)}, Hiroshi UENO^{1,3)*} and Yuji UZUKA^{1,2)}

¹⁾The United Graduate School of Veterinary Sciences, Gifu University, 1-1 Yanagido, Gifu 501-1193, ²⁾Division of Small Animal Surgery, Department of Veterinary Medicine, Faculty of Agriculture, Iwate University, 3-18-8 Ueda, Morioka, Iwate 020-8550 and ³⁾Department of Small Animal Clinical Sciences, Rakuno Gakuen University, 582 Bunkyoudai-Midorimachi, Ebetsu, Hokkaido 069-8501, Japan

(Received 3 October 2010/Accepted 4 December 2010/Published online in J-STAGE 17 December 2010)

ABSTRACT. Delayed wound healing is one of the complications of diabetes mellitus. The present study was performed to investigate the effect of Aloe vera oral administration on open wounds in type 2 diabetic rats. Full thickness open wounds (1.5 × 1.5 cm) were created under general anesthesia on the backs of the rats. These rats were divided into two groups, a control group (Group C) and an Aloe vera oral administration group (Group A). Each wound area was measured on days 1, 2, 4 and 8 postwounding. The stages of wound granulation tissues were evaluated histopathologically. The expression of transforming growth factor (TGF)- β 1 and vascular endothelial growth factor (VEGF) were determined by immunohistochemically. The wounds were significantly contracted in Group A on days 2, 4 and 8 postwounding. Histological results revealed that the inflammatory cell infiltration, angiogenesis, extracellular matrix deposition and epithelialization were promoted in Group A, respectively. The immunohistochemical results revealed that both TGF- β 1 and VEGF protein-positive cells increased in Group A on day 4 postwounding. We concluded that Aloe vera oral administration accelerated wound healing in type 2 diabetic rats.

KEY WORDS: Aloe vera, diabetes, TGF- β 1, VEGF, wound healing.

J. Vet. Med. Sci. 73(5): 583–589, 2011

Aloe vera is a perennial succulent belong to the Lily (Liliaceae) family. This plant has been known as “the healing plant” [9]. Aloe vera has been used for traditional medical purposes in several cultures for millennia [28]. It has been demonstrated that Aloe vera has growth promoting activities [1]. *In vitro*, extracts or components of Aloe vera stimulate the proliferation of several cell types [1, 7]. *In vivo*, recent studies have shown that treatment with whole Aloe vera gel [5–7], extracts as acemannan [24], and G1G1M1D12 [9] resulted in faster healing of wounds. Several reports state that Aloe vera gel has a beneficial influence on the wound healing in both normal and diabetic rats [1, 5, 10, 24]. Reports have stated that it exerts an immunostimulative effect by activating macrophages [12, 32]. In spite of the wide use of Aloe vera as a remedy to enhance wound healing, its mechanism in healing of wounds has not been studied in detail.

Wound healing is a highly complex, but orchestrated cascade of events [6, 30]. It requires a sophisticated interaction among inflammatory cells, biochemical mediators, extracellular matrix (ECM) molecules and the microenvironmental cell population. All of these events are stimulated by a number of mitogens and chemotactic factors [2]. The wound healing process is affected by many factors, either internal or external factors, that may delay or impair the wound healing process. Various growth factors provide the cellular and molecular signals necessary for the normal healing process but are deficient in diabetic wounds [29]. Delayed wound

healing in diabetes mellitus is associated with decreasing the angiogenesis [5], especially, caused by downregulation of vascular endothelial growth factor (VEGF) expression [13]. VEGF promotes all steps in the cascade process of angiogenesis, and experimental evidence suggests that a defect in VEGF regulation is associated with wound healing disorders [2]. Transforming growth factor- β 1 (TGF- β 1) is a multifunctional growth factor, and it enhances the wound contraction rate and ECM production *in vivo* [21]. In diabetic wound fluid, a 55% reduction of TGF- β 1 expression has been shown [18].

Current wound care standards recommend use of hydrophilic nonadherent contact layers for all wounds. Wet dressing products are very absorptive, and they create a moist environment to facilitate healing and reduce the frequency of bandage changes (usually once every 3 to 7 days) [14]. Therefore, it is impossible to apply an Aloe vera topical application everyday during the wet dressing treatment. On the other hand, previous studies by Chithra *et al.* state that Aloe vera is effective to accelerate wound healing by not only topical application but also oral administration [5–7]. Chithra *et al.* also investigate whether Aloe vera enhances wound contraction in both diabetic and nondiabetic rats [5–7]. However, the possible mechanisms of Aloe vera oral administration in healing of wounds have never been reported, especially growth factor expression. Jettanacheawchankit *et al.* investigated the effects of acemannan, a polysaccharide extracted from Aloe vera gel, on the production of keratinocyte growth factor-1 (KGF-1), VEGF and type I collagen production [15]. However, these investigations were performed by *in vitro* studies. According to *in vivo* studies of the wound healing mechanism with Aloe

* CORRESPONDENCE TO: UENO, H., Department of Small Animal Clinical Sciences, Rakuno Gakuen University, 582 Bunkyoudai-Midorimachi, Ebetsu, Hokkaido 069-8501, Japan.
e-mail: uenohiro@rakuno.ac.jp

vera treatment, β -sitosterol from Aloe vera shows to enhance angiogenesis caused by the increase of Von Willibrand factors, VEGF, VEGF receptor and blood vessel matrix laminin [8, 20]. However, these studies used a chick embryo chorioallantoic membrane assay, and chicks are not diabetic animals.

The purposes of this study were to evaluate the effect of Aloe vera oral administration on cutaneous wound healing, especially the expression of TGF- β 1 and VEGF, in a type 2 diabetic rat model.

MATERIALS AND METHODS

Animals: Seven to eight-week-old Goto-Kakizaki (a spontaneous model of diabetes type 2) rats (CLEA Japan Inc., Tokyo, Japan) were used in the present experiment. The animals were housed one per cage for a 1-wk acclimation prior to the experiment. They were fed commercial rat food and water *ad libitum*. These rats were treated in accordance with the guidelines approved by the Animal Use Committee of Gifu University (No. 06017, 07058).

Animal grouping: The animals were randomly assigned into two groups, a control group (Group C; without Aloe vera administration) and an Aloe vera oral administration group (Group A). The number of animals each group is shown in Table 1.

Experimental wounding: All rats were anesthetized with pentobarbital (Nembutal[®], Dainippon Sumitomo Pharma Co., Ltd., Osaka, Japan) at a dose rate of 40 mg/kg by intraperitoneal injection (IP). The hair on the back of each animal was shaved and sterilized with 70% alcohol. Full-thickness skin wound excision of an area measuring 1.5 × 1.5 cm was performed on the back of each animal. The wound was photographed on the day of surgery (day 0) and subsequent days (day 1, 2, 4 and 8 postwounding). The photos were transferred to a computer and converted into the Tagged Information File Format (TIFF) using software (Adobe[®] Photoshop[®] Elements[®] 4.0, Adobe Systems, Tokyo, Japan). The wound area was measured by the NIH ImageJ software (downloaded from <http://www.rsbl.info.nih.gov/ij>). Contraction of the wound was expressed as a percentage of the original wound size (day 0: 100%). Wound dressing was performed under anesthesia with a BAND-AID[®] Kizu Power Pad[™] (Johnson & Johnson, Tokyo, Japan).

Aloe vera administration: Aloe vera was administered

Table 1. The number of animals in each group

	Postwounding period			
	1 day	2 days	4 days	8 days
Group C*	3	4	6	6
Group A [†]	3	4	6	6

* Control group. [†] Aloe vera oral administration group. The entire wound, including a margin of approximately 5 mm of unwounded skin, was excised.

only one time on the 1st day after the wound creation and dressing treatments. Group A rats orally were administered lyophilized Aloe vera powder (Coral Vegetable, Miyakojima, Japan) at a dose of 30 mg/head after dissolving it in 1.5 ml purified water via an oral tube under general anesthesia. The dose of Aloe vera (30 mg/head) was decided as previously described [7].

Tissue collection: Rats were euthanized by overdose of pentobarbital anesthesia (200 mg/kg, IP) on day 1, 2, 4 or 8 postwounding, respectively. The entire wound with a margin of approximately 5 mm of surrounding unwounded skin was excised. These wound samples were used for histopathological and immunohistochemical examination and were fixed for 48 hr in a 10% buffered formalin solution (pH 7.4) and embedded in paraffin.

Histological analysis: Sections (5 μ m) were cut and stained with hematoxylin and eosin (HE) for histopathological examination. Two separate sections of each wound were examined by light microscopy. The areas of the wounds were evaluated in all skin sections in 8 microscopic fields (400 × magnification) by 3 observers blinded to the experimental protocol (Fig. 1). The means \pm standard errors were calculated, respectively. Wound granulation tissue was graded in a blind manner using a modified 0 to 4 Ehrlich and Hunt numerical scale, as previously described [27], modified and internally validated in our laboratory, with 1; representing necrosis, 2; representing inflammatory cell infiltration (white blood cell and fibroblast count) and 3; representing ECM deposition. We used five-point scale to evaluate necrosis and inflammatory cell infiltration (0; no evidence, 1; occasional evidence, 2; light scattering, 3; abundant evidence, 4; confluent cell) as previously described [27]. We also used four-point scale to evaluate ECM deposition (0; no evidence, 1; little ECM deposition, 2; moderate ECM deposition, 3; confluent ECM deposition) as previously described [27].

For immunohistochemistry, the slides were immersed in a covered plastic container with Target Retrieval Solution (pH 9; DAKO, Kyoto, Japan) and placed in autoclave at 121°C for 10 min. Endogenous peroxidase was blocked by a peroxidase blocking reagent (DAKO) for 10 min. Non-specific binding activity was blocked by 10% skim milk

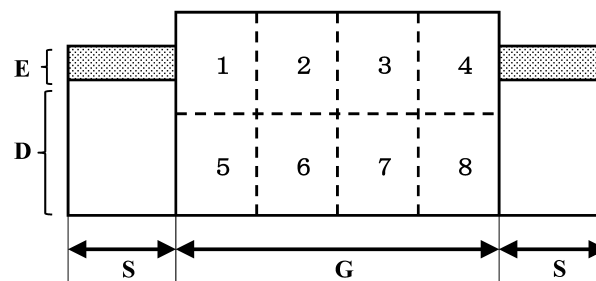


Fig. 1. Schematic illustration of the method of granulation tissue scoring. D: dermis. E: epidermis. G: granulation tissue. S: intact skin. Granulation tissue was divided into 8 fields. Each field was examined histologically at \times 100 magnification.

diluted in phosphate buffered saline (PBS) and incubated for 10 min. Rabbit polyclonal antibody (Quartett Inc., Berlin, Germany) was used as the primary antibody for VEGF. The sections were incubated for 1 hr at room temperature. Rabbit polyclonal antibody (Chemicon International Inc., Temecula, CA, U.S.A.), which was diluted with PBS (1:100), was used as the primary antibody for Factor VIII-related antigen. The sections were incubated for 1 hr at room temperature. Rabbit polyclonal antibody (Santa Cruz Biotechnology Inc., Santa Cruz, CA, U.S.A.), which was diluted with PBS (1:500), was used as the primary antibody for TGF- β 1. The sections were incubated for 1 hr at room temperature. The secondary antibody (Envision system-HRP labeled polymer, DAKO) was applied to the slides for 30 min at room temperature. Diaminobezidine tetrahydrochloride (DAB, DAKO) was used as a chromogen. All slides were counterstained with hematoxylin. Blood vessels were recognized as being positively stained with factor VIII immunohistochemically and containing red blood cells. The number of vessels was counted in 3 high-power fields ($100\times$ magnification) in 2 separate sections. The immunostained sections of TGF- β 1 and VEGF on days 1 and 2 postwounding were displayed at $\times 400$ magnification on a monitor connected to a computer system. Each number of immunopositive cells was counted in 3 high-power fields ($400\times$ magnification) in 2 separate sections by NIH ImageJ. The results were expressed as the average of the positive cells per microscopic field. The means \pm standard errors were calculated, respectively.

Statistical analysis: Comparison of each result between Group C and Group A was first examined by the F-test. If they had equal dispersions, the Student's *t*-test was used. If the dispersion was not equal, the Mann-Whitney U test was used. $P < 0.05$ was considered statistically significant.

RESULTS

Wound contraction: Wound contraction (expressed as a percentage of the wound area to the wound area on day 0) is shown in Fig. 2. The difference between Group C and Group A on day 1 postwounding was not significant. Wound contraction in Group A was accelerated significantly on day 2 ($P = 0.0341$), day 4 ($P = 0.0025$) and day 8 ($P = 0.0089$) postwounding.

Histological analysis: Histological scoring on day 1 and 2 postwounding was impossible because of the peak of the inflammatory stage, which is characterized by condensed inflammatory cells, during this period. On day 4, Group A showed an increase in cellular infiltration and angiogenesis compared with Group C (Fig. 3-a, b). Additionally, the necrotic tissue remained in Group C (Fig. 3-a). On day 8, Group A showed an increase in epithelialization and ECM deposit compared with Group C. A decrease in cellular infiltration and angiogenesis was also observed (Fig. 3-c, d). The results of histological grading scale on days 4 and 8 postwounding are shown in Table 2. Histological evaluation of the wound region revealed that the necrotic tissue

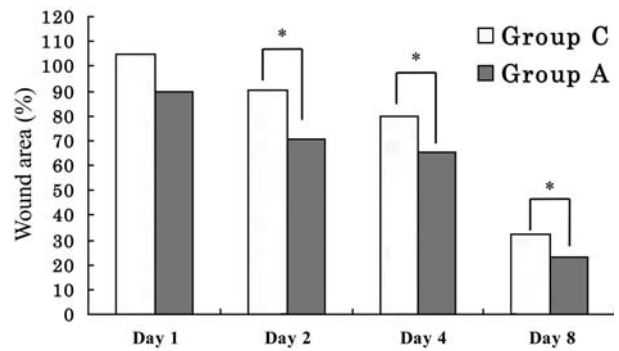


Fig. 2. Wound closure in diabetic rats. The wound closure rate was expressed as the percentage of the wound area compared with that on postoperative day 0 (100%). Values are means \pm SEM. Group C: control group. Group A: Aloe vera oral administration group. * $P < 0.05$ significant difference.

score on day 4 was significantly lower in Group A ($P = 0.0027$). The inflammatory cell infiltration score on day 4 was significantly higher in Group A ($P = 0.0262$). While on day 8, the inflammatory cell score was significantly lower in Group A ($P = 0.0012$). The ECM deposits on day 4 were not well defined, but on day 8, they were significantly higher in Group A ($P = 0.0067$).

The results of blood vessel counting are also shown in Table 2. On day 1 and day 2, counting of blood vessels was impossible because the granulation tissue was not well developed in both the Aloe vera and control groups. On day 4, the number of blood vessels was significantly higher in Group A (153 ± 24) compared with Group C (98 ± 34 , $P = 0.0043$). The number of blood vessels on day 8 was significantly lower in Group A (58 ± 21) compared with Group C (107 ± 24 , $P = 0.0001$).

The number of TGF- β 1 positive cells on day 1 was nearly the same in both Group C (270 ± 44) and Group A (242 ± 16). On day 2, the number of TGF- β 1 positive cells in Group A was significantly higher ($2,578 \pm 131$; Fig. 4-b, d) than that in Group C ($1,615 \pm 277$; Fig. 4-a, c; $P = 0.0008$). These immunoreactive cells against TGF- β 1 antibody were not only round shaped but were also spindle shaped (Fig. 4d). The number of VEGF positive cells on day 1 was nearly the same in Group C (487 ± 236) and Group A (519 ± 215). On day 2, the number of VEGF positive cells in Group A significantly was higher (906 ± 317 ; Fig. 5-b, d) than that in Group C (443 ± 131 ; Fig. 5-a, c; $P = 0.0356$). These immunoreactive cells against VEGF antibody were vascular endothelial cells in the granulation tissue (Fig. 5-d).

DISCUSSION

This study demonstrates the potential of Aloe vera oral administration to treat diabetic wound healing. We investigated whether Aloe vera oral administration significantly accelerates wound contraction compared with the control. This can be a result of enhanced migration of fibroblasts and endothelial cells stimulated by TGF- β 1 and VEGF.




Fig. 3. Histological findings of wound tissue on day 4 and day 8. On day 4, Group A (b) showed a increase in cellular infiltration and angiogenesis (short arrows) compared with Group C (a). Additionally, the necrotic tissue (asterisk) remained in Group C (a). On day 8, Group A (d) showed not only an increase in epithelialization (long arrows) and ECM deposition but also a decrease in cellular infiltration and angiogenesis compared with Group C (c).

Table 2. Histological grading score

Parameter	Day 4 postwounding		Day 8 postwounding	
	Group C	Group A	Group C	Group A
* Necrotic tissue	21 ± 3.8	14 ± 4.7 [†]	2 ± 2.2	1 ± 1.3
* Inflammatory cells	21 ± 2.7	24 ± 2.2 [†]	12 ± 2.9	7 ± 3.3 [†]
* New blood vessels	8 ± 2.9	12 ± 3.5 [†]	16 ± 3.2	11 ± 3.7 [†]
* ECM deposit	Not evaluated	Not evaluated	16 ± 2.9	21 ± 4.4 [†]

* Histological scale: 0; means no evidence, 1; means occasional evidence, 2; means light scattering, 3; means abundant evidence and 4; means confluent cell or fibers. Each parameter was assessed individually in the 8 microscopic fields per slide (See Fig. 1) and two slides per animal. The scores of 8 microscopic fields were totaled, and the means ± standard errors were calculated respectively.

[†] P<0.05 significant difference.

Impaired wound healing is a common complication of diabetes, and several studies have reported that the expression of growth factor or its receptor was decreased in the diabetic animals [1–3, 6, 10, 13, 18, 25, 29]. TGF- β 1 is a multifunctional cytokine and enhances granulation tissue formation in wound healing [18]. A 55% reduction of TGF- β 1 expression in diabetic wound fluid has been shown [3, 18]. In the present study, on day 2 postwounding, the number of TGF- β 1 immunoreactive cells was significantly higher in the Aloe vera oral administration group (Fig. 4).

In the healing wound, TGF- β 1 is produced by leukocytes and macrophages and acts on these cells [16, 31]. In our study, numerous round-shaped cells were immuno-reactive against anti-TGF- β 1 antibody, and these cells were thought to be leukocytes or/and macrophages (Fig. 4-d). Several *in vitro* studies have demonstrated that Aloe vera components like mannose stimulate macrophages through binding to mannose receptor on the surface [12, 19, 22, 23, 32]. Polysaccharides, mannose and acemannan are identified constituents of carbohydrates present in Aloe vera gel [4,

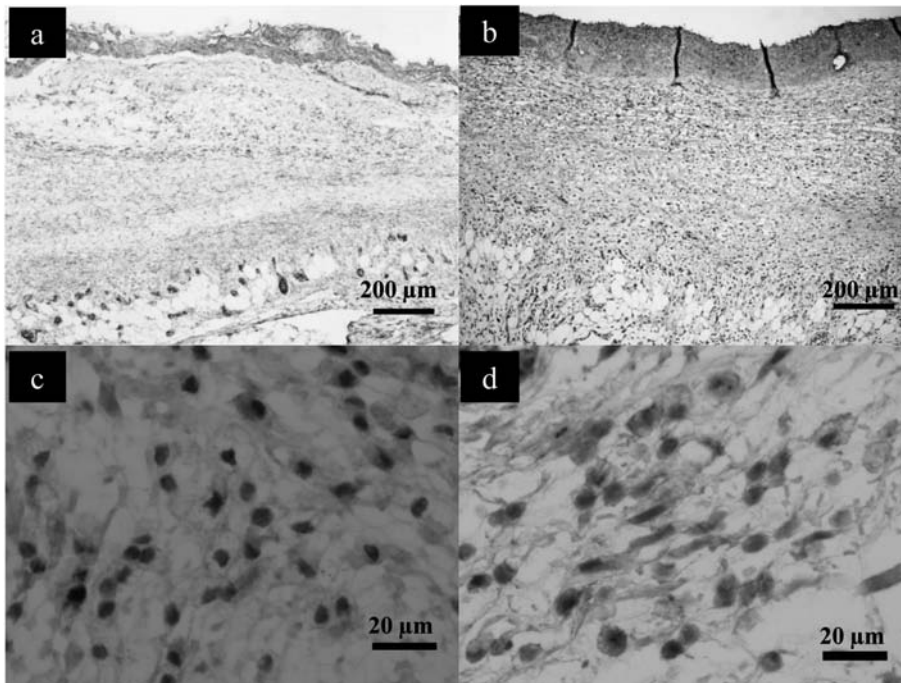


Fig. 4. Immunohistochemical TGF- β 1 staining. Comparison of TGF- β 1 immunoreactivity in Group C (a, c) and Group A (b, d) on day 2 postwounding. Numerous round and spindle cells were immunoreactive in Group A compared with Group C.

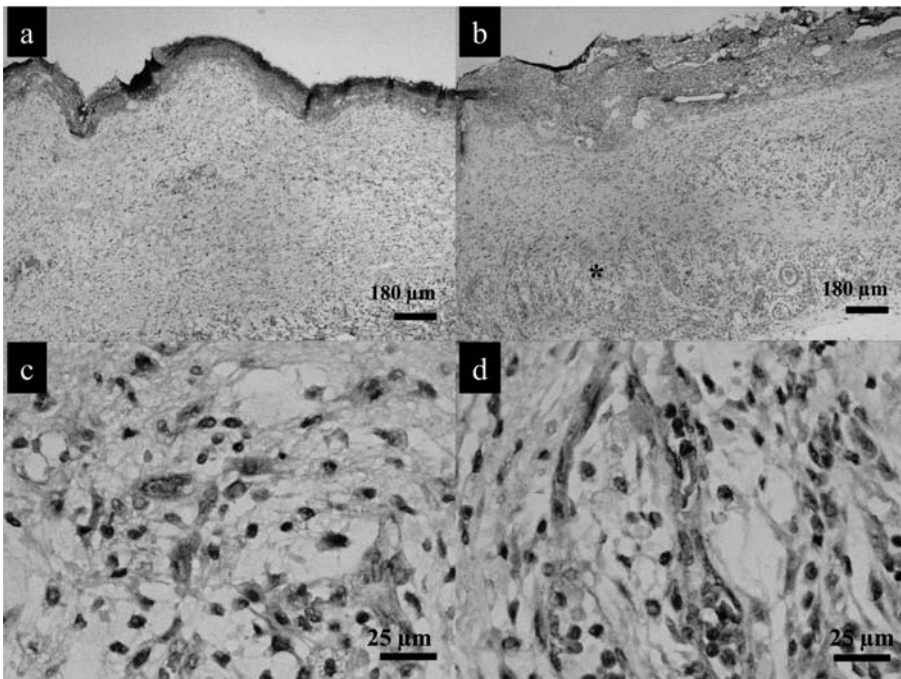


Fig. 5. Immunohistochemical VEGF staining. Comparison of VEGF immunoreactivity in Group C (a, c) and Group A (b, d) on day 2 postwounding. There are numerous immunopositive cells in Group A compared with Group C. Additionally, angiogenesis was increased in Group A (asterisk).

28]. The possible explanation for the acceleration of TGF- β 1 production could be that these constituents of Aloe vera, when administered orally, would activate wound macrophages by binding to mannose receptor.

In our immunohistochemical study, numerous spindle-shaped cells were also immunoreactive against anti-TGF- β 1 antibody, and these cells were thought to be fibroblasts (Fig. 4-d). TGF- β 1 is also produced by fibroblasts and acts on these cells [31]. TGF- β 1 enhances collagen formation in wound healing [18]. In the present study, Group A showed an increase in ECM deposition on day 8 compared with Group C histopathologically (Fig. 3-c, d). Jettanacheawchankit *et al.* investigated the effects of acemannan on gingival fibroblasts *in vitro*, and type I collagen production of gingival fibroblasts is increased by acemannan stimulation [15]. Therefore, Aloe vera oral administration may increase ECM production by not only a direct effect but also TGF- β 1 stimulation of wound fibroblasts. In our study, Aloe vera oral administration increased in wound contraction on days 2, 4, and 8 postwounding (Fig. 2). Granulation tissue contraction relates to myofibroblast proliferation [17, 26]. Myofibroblasts appear to differentiate from fibroblasts by acquiring the smooth muscle cell actin isoform α -smooth muscle actin [31]. Several studies investigated whether fibroblasts become myofibroblasts due to TGF- β 1 stimulation [11, 16]. In our study, the number of TGF- β 1 immunoreactive cells in the newly formed granulation tissue was significantly higher in the Aloe vera oral administration group (Fig. 4). Therefore, Aloe vera oral administration has the possibility to accelerate the proliferation to myofibroblasts due to TGF- β 1 stimulation. To confirm our speculation that the differentiation of fibroblast to myofibroblast could be the candidate, study of the expression of α -smooth actin is still required.

VEGF promotes all steps in the cascade process of angiogenesis [2]. Frank *et al.* provided the evidence for a defect in VEGF regulation during wound healing in genetically diabetic db/db mice, which are characterized by a severe delay in skin repair [13]. In the present study, the number of VEGF immunoreactive endothelial cells in the granulation tissue was significantly increased in Aloe vera oral administration group on day 2 postwounding (Fig. 5-d). Additionally, the Aloe vera oral administration accelerated angiogenesis significantly on day 4 postwounding (Table 3). From our results, Aloe vera oral administration would have the possibility to accelerate angiogenesis by upregulation of VEGF expression in diabetic rats. Jettanacheawchankit *et al.* investigated whether VEGF production of gingival fibroblasts is increased by acemannan stimulation [15]. The possible explanation for the acceleration of VEGF expression could be that the constituents of Aloe vera would activate wound fibroblasts.

In conclusion, we suspected that Aloe vera oral administration would provide a systemic effect through the increase of growth factor production and angiogenesis. This finding opens an avenue for further clinical studies on the improvement of diabetic wound healing and another delayed wound

healing problems such as radiated wounds after Aloe vera oral administration.

ACKNOWLEDGMENT. This work was supported by research funds from Miyakojima City (Okinawa, Japan).

REFERENCES

1. Abdullah, K. M., Abdullah, A., Johnson, M. L., Bilski, J. J., Petry, K., Redmer, D. A., Reynolds, L. P. and Grazul-Bilska, A. T. 2003. Effects of Aloe vera open gap junctional intercellular communication and proliferation of human diabetic and nondiabetic skin fibroblasts. *J. Altern. Complement. Med.* **9**: 711–718.
2. Altavilla, D., Saitta, A., Cucinotta, D., Galeano, M., Deodato, B., Colonna, M., Torre, V., Russo, G., Sardella, A., Urna, G., Campo, G. M., Cavallari, V., Squadrito, G. and Squadrito, F. 2001. Inhibition of lipid peroxidation restores impaired vascular endothelial growth factor expression and stimulates wound healing and angiogenesis in the genetically diabetic mouse. *Diabetes* **50**: 667–674.
3. Bitar, M. S. and Labbad, Z. N. 1996. Transforming growth factor-beta and insulin-like growth factor-I in relation to diabetes-induced impairment of wound healing. *J. Surg. Res.* **61**: 113–119.
4. Boudreau, M. D. and Beland, F. A. 2006. An evaluation of the biological and toxicological properties of Aloe Barbadensis (Miller), Aloe vera. *J. Environ. Sci. Health C. Environ. Carcinog. Ecotoxicol. Rev.* **24**: 103–154.
5. Chithra, P., Sajithlal, G. B. and Chandrakasan, G. 1998. Influence of Aloe vera on the glycosaminoglycans in the matrix of healing dermal wounds in rats. *J. Ethnopharmacol.* **59**: 179–186.
6. Chithra, P., Sajithlal, G. B. and Chandrakasan, G. 1998. Influence of Aloe vera on the healing of dermal wounds in diabetic rats. *J. Ethnopharmacol.* **59**: 195–201.
7. Chithra, P., Sajithlal, G. B. and Chandrakasan, G. 1998. Influence of Aloe vera on collagen characteristics in healing dermal wounds in rats. *Mol. Cell Biochem.* **181**: 71–76.
8. Choi, S. W., Kim, K. W., Choi, J. S., Han, S. T., Park, Y. I., Lee, S. K., Kim, J. S. and Chung M. H. 2002. Angiogenic activity of β -sitosterol in the ischaemia/reperfusion-damaged brain in *Mongolian Gerbil*. *Planta Med.* **68**: 330–335.
9. Choi, S. W., Son, B. W., Son, Y. S., Park, Y. I., Lee, S. K. and Chung, M. H. 2001. The wound-healing effect of a glycoprotein fraction isolated from Aloe vera. *Br. J. Dermatol.* **145**: 535–545.
10. Davis, R. H., Leitner, M. G. and Russo, J. M. 1988. Aloe vera: a natural approach for treating wound, edema and pain in diabetes. *J. Am. Podiatr. Med. Assoc.* **72**: 60–68.
11. Desmouliere, A., Geinoz, A., Gabbiani, F. and Gabbiani, G. 1993. Transforming growth factor- β 1 induces β -smooth muscle actin expression in granulation tissue myofibroblasts and in quiescent and growing cultured fibroblasts. *J. Cell. Biol.* **122**: 103–111.
12. Djeraba, A. and Quere, P. 2000. *In vivo* macrophage activation in chickens with Acemannan, a complex carbohydrate extracted from Aloe vera. *Int. J. Immunopharmacol.* **22**: 365–372.
13. Frank, S., Hubner, G., Dreier, G., Longaker, M. T., Greenhalgh, D. G. and Werner, S. 1995. Regulation of vascular endothelial growth factor expression in cultured keratinocytes:

- implications for normal and impaired wound healing. *J. Biol. Chem.* **270**: 12607–12613.
14. Hedlund, C. S. 2007. General Principles and techniques. pp. 159–192. *In: Small Animal Surgery*, 3rd ed. (Fossum, T. W. ed), Mosby Elsevier, St. Louis.
 15. Jettanacheawchankit, S., Sasithanasate, S., Sangvanich, P., Banlunara, W. and Thunyakitpisal, P. 2009. Acemannan stimulates gingival fibroblast proliferation; expressions of keratinocyte growth factor-1, vascular endothelial growth factor, and type I collagen; and wound healing. *J. Pharmacol. Sci.* **109**: 525–531.
 16. Kwon, A. H., Qiu, Z. and Hirao, Y. 2007. Topical application of plasma fibronectin in full-thickness skin wound healing in rats. *Exp. Biol. Med.* **232**: 935–941.
 17. Kwon, Y. B., Kim, H. W., Roh, D. H., Yoon, S. Y., Baek, R. M., Kim, J. Y., Kweon, H., Lee, K. G., Park, Y. H. and Lee, J. H. 2006. Topical application of epidermal growth factor accelerates wound healing by myofibroblast proliferation and collagen synthesis in rat. *J. Vet. Sci.* **7**: 105–109.
 18. Lee, P. Y., Chesnoy, S. and Huang, L. 2004. Electroporation delivery of TGF- β 1 gene works synergistically with electric therapy to enhance diabetic wound healing in db/db mice. *J. Invest. Dermatol.* **123**: 791–798.
 19. Liu, C., Leung, M. Y., Koon, J. C., Zhu, L. F., Hui, Y. Z., Yu, B. and Fung, K. P. 2006. Macrophage activation by polysaccharide biological response modifier isolated from Aloe vera L. var. chinensis (Haw.) Berg. *Int. J. Immunopharmacol.* **6**: 1634–1641.
 20. Moon, E. J., Lee, Y. M., Lee, O. H., Lee, M. J., Lee, S. K., Chung, M. H., Park, Y. I., Sung, C. K., Choi, J. S. and Kim, K. W. 1999. A novel angiogenic factor derived from Aloe vera gel: β -sitosterol, a plant sterol. *Angiogenesis* **3**: 117–123.
 21. Mustoe, T. A., Pierce, G. F., Morishima, C. and Deuel, T. F. 1991. Growth factor-induced acceleration of tissue repair through direct and inductive activities in a rabbit dermal ulcer model. *J. Clin. Invest.* **87**: 694–703.
 22. Pan, S., An, P., Zhang, R., He, X., Yin, G. and Min, W. 2002. Etk/Bmx as a tumor necrosis factor receptor type 2-specific kinase: Role in endothelial cell migration and angiogenesis. *Mol. Cell. Biol.* **22**: 7512–7523.
 23. Qiu, Z., Jones, K., Wylie, M., Jia, Q. and Orndorff, S. 2000. Modified Aloe barbadensis polysaccharide with immunoregulatory activity. *Planta Med.* **66**: 152–156.
 24. Roberts, D. B. and Travis, E. L. 1995. Acemannan-containing wound dressing gel reduces radiation-induced skin reactions in C3H mice. *Int. J. Radiat. Oncol. Biol. Phys.* **32**: 1047–1052.
 25. Saaristo, A., Tammela, T., Farkkila, A., Karkkainen M., Suominen, E., Yla, S. and Alitalo, K. 2006. Vascular endothelial growth factor-C accelerates diabetic wound healing. *Am. J. Pathol.* **169**: 1080–1087.
 26. Sidhu, G. S., Singh, A. K., Banaudha, K. K., Gaddipati, J. P., Patnaik, G. K. and Maheshwari, R. K. 1999. Arnebin-1 accelerates normal and hydrocortisone-induced impaired wound healing. *J. Invest. Dermatol.* **113**: 773–781.
 27. Turan, M., Saraydyn, S., Bulut, H., Elagoz, S., Cetinkaya, O., Karadatyi, K., Canbay, E. and Sen, M. 2004. Do vascular endothelial growth factor promote phenytoin's wound healing effect in rat? An immunohistochemical and histopathologic study. *Dermatol. Surg.* **30**: 1303–1309.
 28. Vogler, B. K. 1999. Aloe vera: a systemic review of its clinical effectiveness. *Br. J. Gen. Pract.* **49**: 823–828.
 29. Wang, W., Lin, S., Xiao, Y., Huang, Y., Tan, Y., Cai, L. and Li, X. 2008. Acceleration of diabetic wound healing with chitosan-crosslinked collagen sponge containing recombinant acidic fibroblast growth factor in healing-impaired STZ diabetic rats. *Life Sci.* **82**: 190–204.
 30. Werner, S. and Grose, R. 2003. Regulation of wound healing by growth factors and cytokines. *Physiol Rev.* **83**: 835–870.
 31. Werner, S., Krieg, T. and Smola, H. 2007. Keratinocyte-fibroblast interactions in wound healing. *J. Invest. Dermatol.* **127**: 998–1008.
 32. Zhang, L. and Tizard, I. R. 1996. Activation of a mouse macrophage cell line by acemannan: the major carbohydrate fraction from Aloe vera gel. *Immunopharmacology* **35**: 119–128.